

# Case Reports on Emergency Treatment of Cardiovascular Syndromes Through Heparin-Mediated Low-Density Lipoprotein/Fibrinogen Precipitation: A New Approach to Augment Cerebral and Myocardial Salvage

\*Beate Roxane Jaeger, †Eckart Kreuzer, ‡Andreas Knez, ‡Andreas Leber,  
†Peter Überfuhr, \*Monika Börner, §Petra Milz, †Bruno Reichart, and \*Dietrich Seidel

\*Institut für Klinische Chemie, †Abteilung für Herzchirurgie, ‡Medizinische Klinik I, Kardiologie, and the §Abteilung für Neuroradiologie, Universitätsklinikum Großhadern, Ludwig-Maximilians-Universität München, München, Germany

**Abstract:** We report the first experiences with HELP apheresis as an emergency treatment for acute cardiovascular syndromes; two patients who were not eligible for lysis therapy and catheter intervention were treated with HELP apheresis instead. Both patients had a most severe, generalized atherosclerosis and reached the hospital too late for conventional measures. In both cases, the use of

the apheresis dramatically improved the clinical situation to such an extent that the possibilities of this apheresis system urge further investigation. **Key Words:** Myocardial infarction—Unstable angina—Stroke—GIIb/IIIa inhibitors—Fibrinolytic drugs—Low-density lipoprotein apheresis—Plasma treatment.

## INTRODUCTION

Patients with cerebral or myocardial infarction require early and effective reperfusion of the infarcted area. Reperfusion of the occluded artery restores oxygen and nutrient supply to the infarcted area, which improves cerebral or cardiac function and survival, respectively (1). Until now, there were two main strategies of reperfusion treatment: first, a *mechanical* approach, including cardiologic (percutaneous transluminal coronary angioplasty [PTCA]/percutaneous transluminal angioplasty [PTA], stenting) or surgical interventions (carotid surgery, coronary bypass operation); second, a pharmacological approach, including various antithrombotic drugs such as fibrinolytic agents (abciximab, t-PA, reteplase), heparin, or inhibitors of platelet aggregation (aspirin, clopidogrel, GIIb/IIIa inhibitors). Notwithstanding the merits of either approach, both strategies have their well-known limitations in the

problem of allocation, or rather access to the infarction, the short therapeutic time window and the risk of serious complications (1).

We are presenting a new approach to the treatment of acute cardiovascular syndromes with which we have already found beneficial in the secondary prevention of coronary heart disease (2–7). The method is called *Heparin-mediated Extracorporeal LDL/Fibrinogen Precipitation* or the HELP system (HD Secura R, B. Braun Melsungen AG, Melsungen, Germany) (2–4). It is a form of lipid apheresis that combines a plasmapheresis unit for separation of the plasma, a pump for the controlled addition of heparin (>100,000 U/h) and acetate buffer to the extracorporeal circuit, a precipitation filter for retaining fibrinogen, other clotting factors, C-reactive protein and low-density lipoprotein (LDL)-cholesterol after precipitation through heparin, a heparin adsorber to bind excess heparin from the plasma, and finally a dialysis/ultrafiltration unit for restoration of the physiological pH of plasma after treatment.

The system is technically standardized and has been in clinical use for more than 15 years. Its safety and efficacy have been proven by numerous studies (2–7), by treatment of approximately 1,000 patients, and by more than 200,000 treatments overall.

Received March 2002; revised June 2002.

Address correspondence and reprint requests to Dr. Beate Roxane Jaeger, Institut für Klinische Chemie, Klinikum Großhadern, Ludwig-Maximilians-Universität München, Marchioninstr. 15, D-81377 München, Germany. E-mail: Beate.Jaeger@klch.med.uni-muenchen.de

The two cases described here emphasize the possibilities of HELP apheresis as a complement or an alternative to traditional therapies for stroke, unstable angina, and myocardial infarction.

### CASE I

A 55 year old male patient was admitted to our hospital with left side hemiparesis, accompanied by hemihyperesthesia and apraxia of the left arm, central paresis of the facialis nerve, pronounced dysarthria, and a lack of orientation. The reason for the stroke was an occlusion of the right cerebri media artery, leading to infarction of the gyrus precentralis, postcentralis, and the edge of gyrus frontalis. Figure 1 shows the magnetic resonance imaging on admission. An old infarction of the brainstem and microangiopathic changes were also present; Doppler sonography showed an occlusion of the right carotid internal artery. Six months earlier this vessel was already 80% occluded.

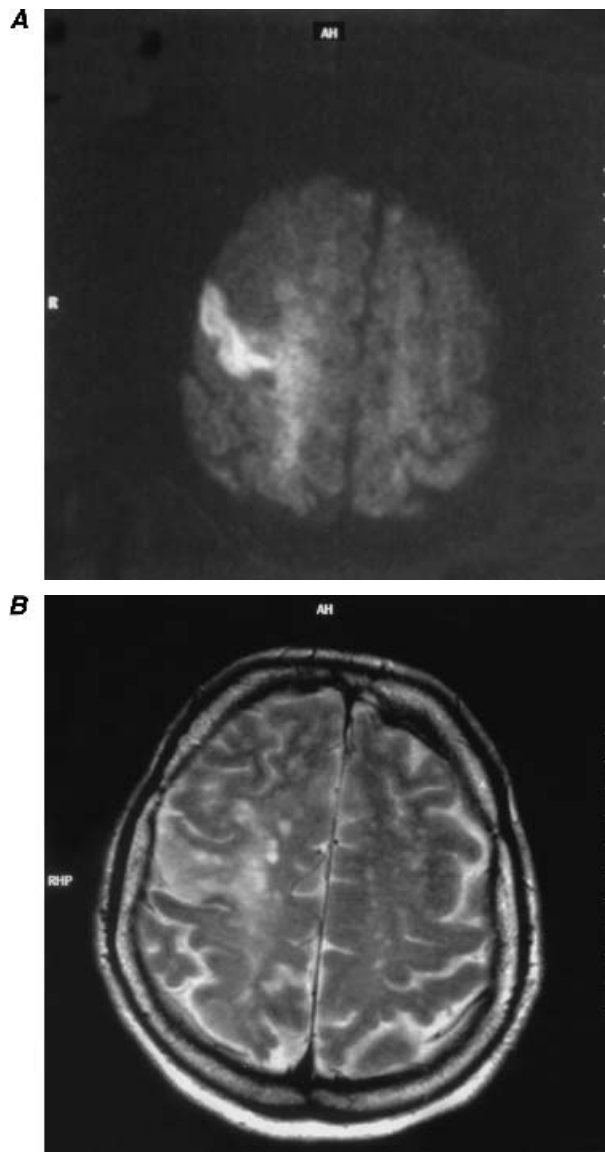
Because the stroke symptoms had begun 2 days earlier, it was too late for thrombolysis. The patient was treated overnight with full-dose heparin. Because there was no relevant improvement the next day, we decided to attempt treatment with HELP apheresis. This one treatment had the following effects: during the 2 h long apheresis, the patient's dysarthria improved drastically. After the apheresis, the patient articulated normally. Also, he could walk without any form of assistance and had regained his muscle force. His orientation improved (i.e., he now remembered his telephone number and other details). The patient was stable over the following days and left the hospital within 1 week. A slight apraxia of his hand remained. During the next visit, the patient reported minor memory problems but not in relation to his job as a night porter. One month later, his memory caused no further problems.

The good outcome in this case is remarkable because this patient had a most severe, generalized atherosclerosis with previous strokes, severe lower extremity arterial disease, and ischemic cardiomyopathy with subsequent heart transplantation in 1991. One kidney was extirpated because he had urothelial cancer.

### CASE II

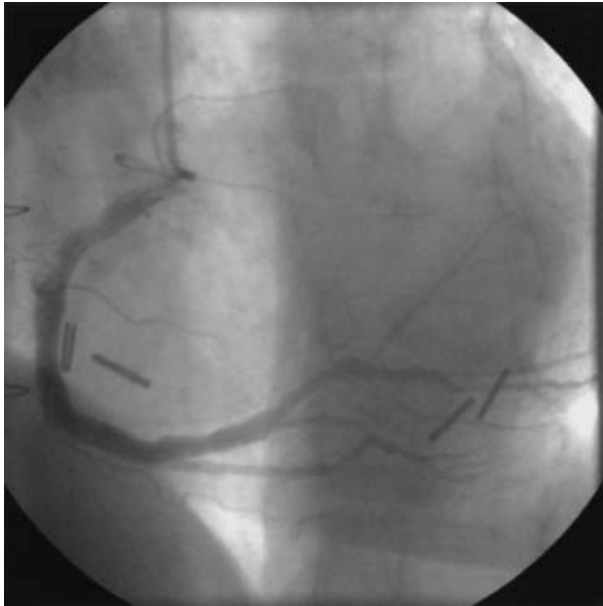
A 60 year old female patient was admitted to the hospital with chest pain. She had sustained anginal pain at rest for 3 days, aggravated by an influenza-like infection with fever and bronchitis.

The electrocardiogram showed a sinus tachycardia of 119/min; low voltage; QRS axis to the left:  $-70^\circ$ , left anterior fascicular block and right bundle branch



**FIG. 1.** Case I: Diffusion imaging of the brain on admission, showing the fresh territorial infarction of the right cerebri media artery (white area with reduced diffusion caused by the cytotoxic edema) (A). Case I: Magnetic resonance imaging scan of the brain on admission, showing the fresh infarction of the right cerebri media artery (T2-weighted image) and multiple white matter lesions reflecting old microangiopathic lesions (B).

block; ST segment elevation and Q in II; aVF, and V6; R reduction in V5; and ST segment depression in V1–2. The laboratory analysis confirmed the diagnosis of a myocardial infarction. On admission, troponin I was 244 ng/mL (reference:  $<0.5$  ng/mL), the creatine kinase (CK) activity 377 U/L (ref.  $<80$  U/L) to which the cardiac-specific isoenzyme of the CK containing M and B subunits (CK-MB) contributed 15% (Table 1). Aspartate aminotransferase (GOT) was 62 U/L (ref.  $<15$  U/L), LDH 666 U/L (ref.  $<240$  U/L) (Table 1).



**FIG. 2.** Case II: Coronary angiography in Sones technique, showing the right coronary artery with diffuse transplant-associated coronary artery disease and distal occlusion (RAO projection).

Coronary angiography revealed a distal occlusion of the right coronary artery that most probably accounted for the acute symptoms but was not accessible to intervention (Fig. 2). The patient had a history of severe, diffuse transplant-associated coronary artery disease after heart transplantation 1994. The left ventricular function was reduced but not quantified by ventriculography with regard to her elevated creatinine levels of 3.7 mg/dL.

It was too late for thrombolytic therapy because of the onset of symptoms 3 days prior. We performed one HELP apheresis which had the following immediate effects. Her anginal pain disappeared, and the

monitor recorded less irregular heartbeats. Pulse and blood pressure remained stable. After only 2 hours of treatment, the creatine kinase (CK) activity had dropped by 65% and CK mass by 72% (Table 1). The myocardial markers again increased several hours after apheresis but not up to the initial level (Table 1). This kind of *wash out* effect can be also observed after successful PTCA or thrombolytic treatment. In parallel, a pronounced acute-phase reaction could be observed: C-reactive protein (CRP) was 24.7 mg/dL (ref. <0.5 mg/dL), fibrinogen was 787 mg/dL (ref. < 400 mg/dL), presumably triggered by the preceding infection. Thrombocyte aggregation was raised as indicated by a curtailed in vitro bleeding time of 51 s (ref. 71–118 s for adenosine diphosphate [ADP] [8]). An enormous amount of fibrinogen (25.4 g) was precipitated by the apheresis.

HELP apheresis lowered plasma fibrinogen by 81%, CRP by 79%, and also the global clotting activity from normal values to a prothrombin time (PT) of 39% and an activated thromboplastin time (aPTT) to 83 s (Table 1). Contrary to the usual course in unstable angina with ensuing infarction, the patient recovered extraordinarily fast; heparin infusion was stopped the next day. She was discharged after 1 week. Three months later she reported no health problems; in the mean time, left ventricular function measured by echocardiography was in the lower normal range.

## DISCUSSION

The positive outcome in both cases and ongoing studies urge treatment at a preliminary stage because there are obvious and potentially substantial implications for the treatment of acute cardiovascular syndromes.

**TABLE 1.** Clinical laboratory values during treatment

Therapy	HELP treatment			I.V. heparin and nitrates until day 2				
	Before Day 1: 11:00 h	After 13:00 h	Reduction by HELP	Day 1, 20:00 h	Day 2	Day 3	Day 4	Day 7
CK [U/L]	377	133	-65%	174	143	70	40	16
CK-MB [U/L]	57	20	-65%	35	23	—	—	—
CK mass [ng/mL]	127	35	-72%	42	28	8.8	3.3	1.1
Troponin I [U/L]	244	180	-25%	184	215	134	103	28
Creatinine [mg/dL]	3.7	2.9	-22%	3.5	3.0	2.6	3.1	2.7
Fibrinogen [U/L]	787	150	-81%	310	439	487	515	405
CRP [mg/dL]	24.7	5.2	-79%	11.0	7.8	2.7	1.9	1.0
Lp(a) [mg/dL]	100	20	-80%	—	—	83	62	—
PT [%]	80	39	-51%	75	90	85	80	80
aPTT [s]	39	83	+106%	126	39	51	39	39
GOT [U/L]	62	—	—	47	33	17	11	11
LDH [U/L]	666	—	—	658	541	—	244	247

CK: creatine kinase, CK-MB: cardiac-specific isoenzyme of the creatine kinase containing M and B subunits, CK mass: creatine kinase mass, CRP: C-reactive protein, Lp(a): lipoprotein (a), PT: prothrombin time, aPTT: activated partial thromboplastin time, GOT: aspartate aminotransferase, LDH: lactate dehydrogenase.

Energy production of cerebral and myocardial cells is oxygen dependent with very little anaerobic reserve. The oxygen supply can be augmented by restoring forward blood flow or by increasing the collateral circulation. HELP apheresis contributes in both ways: There is no doubt as to the apheresis promoting the disintegration of the occluding thrombus. We see that approximately 80% of plasma fibrinogen (the essential link for platelet-platelet-interaction), 80% of von Willebrand factor (the essential link for platelet-endothelial-interaction), 65% of factor XIII (the essential stabilizer of the fibrin strands), 80% of prothrombin (the precursor of the key enzyme of coagulation and platelet aggregation), 50% of factor VII (the trigger of the intrinsic coagulation cascade), 79% of CRP (the stimulus for tissue factor expression by macrophages), 80% of LDL-C (the critical compound of the unstable plaque), and 80% of lipoprotein (a) (the thrombogenic competitor of plasminogen) has been washed out (Table 1).

The abrupt reduction of the blood concentration of the aforementioned blood constituents has a direct impact on the concentration within the thrombus, because, according to Raoult's law of osmotic diffusion between two solutions, every concentration difference seeks a balance. Both solutions equalize by diffusion. Consequently, removing the clotting factors from the blood exerts suction onto the links of the thrombus that *melts* the thrombus.

Thrombus formation occurs as a dynamic process over several days, and metabolic changes such as hibernation or stunning protect the surrounding ischemic tissue; therefore, treatment might still prove beneficial after 2 or 3 days. Efficacy is limited by increasing the stability of the thrombus. Stability largely depends on the presence of factor XIII. The simultaneous reduction of von Willebrand factor and factor VII accelerates thrombus disintegration, because both factors fix the thrombus on the ruptured plaque or the vessel wall, respectively (9,10).

The intensity of apheresis treatment regarding the percentage of reduction of clotting factors and lipoproteins can be individually controlled: the more the clotting factor concentration is lowered, the faster the thrombus dissolves. Theoretically, plasma fibrinogen could be washed out completely. As to fibrinogen, we refer to a threshold concentration of 80 mg/dL for safety reasons. Treatment normally lasts 2 hours, but more than 90% of the precipitation occurs in the first hour. It should be mentioned that the HELP system does not induce a systemic fibrinolytic state comparable to reteplase or streptokinase (9,10) which explains why this treatment never pro-

voked serious bleeding complications in more than 200,000 treatments worldwide.

Besides the postulated effects on forward blood flow, treatment improves the collateral blood flow. We know from previous studies that a single HELP apheresis leads to 9.7–19.9% more cerebral blood flow verified by  $^{133}\text{Xe}$ -SPECT study (11), 14% more cerebral  $\text{CO}_2$  reactivity using transcranial Doppler during hypercapnia (12), 25–30% more coronary blood flow and flow reserve by  $^{13}\text{N}$ -ammonia PET studies (13,14), 16–34% higher muscle oxygen tension (7), and 33–50% higher transcutaneously measured partial pressure of oxygen (15).

Blood flow velocity increases because a single apheresis lowers plasma viscosity by 15–20% and erythrocyte aggregation by 60% which is a consequence of fibrinogen removal (7,10). A better microcirculation ensues, because capillary perfusion is determined mainly by plasma viscosity. The hematocrit here is a mere 10% (Fahraeus-Lindquist effect). Less erythrocyte aggregation and plasma viscosity facilitates oxygen delivery. This also facilitates clearance of toxic metabolic products from the infarcted area. Furthermore, the reduction of LDL-cholesterol beneficially affects endothelial function and flow reserve (13).

It is likely that all these effects do their part to limit *ischemia at distance* and may also prevent secondary deterioration. One might take advantage of the HELP apheresis in that it reaches vascular territories that are not accessible to cardiologic or surgical interventions. Lehner and Walzl (11) were first to study patients with multiinfarct disease and cerebral infarctions: repeated HELP treatment significantly improved neurological recovery as studied with the Mathew scale and the Mini-Mental-State Examination.

Notably, the available time span for application of HELP treatment is not as limited as it is for fibrinolytic drugs. There is evidence from long-lasting experience in the chronic treatment of 1,000 patients and from previous studies confirming the HELP treatment is very well tolerated and compatible with other interventions (PTCA and bypass surgery) or standard medical therapy (2–6). The treatment is easy to handle and ready for application.

## CONCLUSIONS

Our preliminary results indicate that the HELP therapy may become an important complementary or alternative approach for patients experiencing an acute cardiovascular event. The effectiveness of HELP apheresis in stroke, unstable angina, and

myocardial infarction needs to be further investigated.

**Acknowledgment:** We are deeply indebted to the skillful support of the members of the HELP team: Mrs. Irmgard Jacobsen, Mrs. Hermine Worm, Mrs. Maria Schuster, and Mrs. Evelyn Worm.

## REFERENCES

- Ryan TJ, Anderson JL, Antman EM, Braniff BA, Brooks NH, Califf RM, Hillis LD, Hiratzka LF, Rapaport E, Riegel BJ, Russell RO, Smith EE, Weaver WD. ACC/AHA guidelines for the management of patients with acute myocardial infarction: Executive summary. *Circulation* 1996;94:2341–50.
- Seidel D, Armstrong VW, Schuff-Werner P for the H.E.L.P. Study Group. The H.E.L.P.-LDL-apheresis multicentre study, an angiographically assessed trial on the role of LDL-apheresis in the secondary prevention of coronary heart disease. I. Evaluation of safety and cholesterol-lowering effects during the first 12 months. *Eur J Clin Invest* 1991;21:375–83.
- Seidel D. The H.E.L.P. System, a new therapeutic tool in the treatment of atherosclerosis. In: Seidel D, ed. *H.E.L.P. Report 1994–10 Years of Clinical Experience*. München: MMV Medizin Verlag GmbH, 1994:1–12.
- Schuff-Werner P, Gohlke H, Bartmann, Baggio G, Corti MC, Dinsbacher A, Eisenhauer T, Grützmacher P, Keller C, Kettner U, Kleophas W, Köster W, Olbricht CJ, Richter WO, Seidel D, the H.E.L.P. Study Group. The H.E.L.P.-apheresis multicentre study, an angiographically assessed trial on the role of LDL-apheresis in the secondary prevention of coronary heart disease. II. Final evaluation of the effect of regular treatment on LDL-cholesterol plasma concentrations and the course of coronary heart disease. *Eur J Clin Invest* 1994;24:724–32.
- Jaeger BR, Meiser B, Nagel D, Überfuhr P, Thiery J, Brandl U, Brückner W, von Scheidt W, Kreuzer E, Steinbeck G, Reichart B, Seidel D. Aggressive lowering of fibrinogen and cholesterol in the prevention of graft vessel disease after heart transplantation. *Circulation* 1997;96(Suppl. II):154–8.
- Jaeger BR, Marx P, Pfefferkorn T, Hamann FG, Seidel D. Heparin-induced extracorporeal LDL/Fibrinogen Precipitation–H.E.L.P. in coronary and cerebral ischemia. *Acta Neurochir* 1999;73(Suppl.):81–4.
- Schuff-Werner P, Schütz E, Seyde WC, Eisenhauer T, Janning G, Armstrong VW, Seidel D. Improved hemorheology associated with a reduction in plasma fibrinogen and LDL in patients being treated by heparin-induced extracorporeal LDL precipitation (H.E.L.P.). *Eur J Clin Invest* 1989;19:30–7.
- Kratzer MAA, Born GVR. Simulation of primary hemostasis in vitro. *Haemostasis* 1985;15:357–62.
- Jaeger BR, Göhring P, Uhrig S, Lohse P, Thiery J, Seidel D. An extracorporeal device to remove clotting factors from the blood circulation via precipitation with heparin (H.E.L.P.). *Circulation* 1998;98(Suppl.):2948.
- Jaeger BR, Goehring P, Schirmer J, Uhrig S, Lohse P, Kreuzer E, Reichart B, Seidel D. Consistent lowering of clotting factors for the treatment of acute cardiovascular syndromes and hypercoagulability—a different pathophysiologic approach. *Ther Apher* 2001;5:252–9.
- Walzl M, Lechner H, Walzl B, Schied G. Improved recovery of cerebral infarctions after plasmapheretic reduction of lipids and fibrinogen. *Stroke* 1993;24:1447–51.
- Pfefferkorn TK, Knüppel T, Jaeger BR, Thiery J, Hamann G. Increased CO<sub>2</sub>-reactivity after heparin-mediated extracorporeal LDL precipitation in patients with coronary heart disease and hypercholesterolemia. *Stroke* 1999;30:1802–6.
- Mellwig KP, Baller D, Gleichmann U, Moll D, Betker S, Weise R, Notohamiprodjo G. Improvement of coronary vasodilation capacity through single LDL apheresis. *Atherosclerosis* 1998;139:173–8.
- Jaeger BR, Bengel F, Odaka K, Überfuhr P, Kreuzer E, Reichart B, Schwaiger M, Seidel D. Der akute Einfluß der H.E.L.P.—Apherese auf den myokardialen Blutfluß bei herztransplantierten Patienten. *Z Kardiol* 2000;4:83.
- Kleophas W, Leschke M, Tschöpe D, Schauseil S. Akute Wirkungen der extrakorporalen LDL-Cholesterin- und Fibrinogen-Elimination auf Blut rheologie und Mikrozirkulation. *Dtsch Med Wschr* 1990;115:7–11.

